

## A Case of Carcinoma Oesophagus with Spontaneous Oesophagopleural Fistula

*Dr. Rohit Singh<sup>1\*</sup>, Dr. Ashish Deshmukh<sup>2</sup>, Dr. Sunil Jadhav<sup>3</sup>, Dr. S. Kasat<sup>4</sup>, Dr. Hafiz Deshmukh<sup>4</sup>*

Resident<sup>1\*</sup>, Professor and HOD<sup>2</sup>, Associate Professor<sup>3</sup>, Assistant Professor<sup>4</sup>, Department of Respiratory medicine Mahatma Gandhi Missions Medical college & Hospital Aurangabad, Maharashtra.

- 1. INTRODUCTION:-** Oesophagopleural fistula is a condition which occurs secondary to oesophageal surgery, instrumentation, malignancy or a rare pneumonectomy complication. The radiological signs of the EPF depend upon site, duration, and severity of perforation; and more importantly, the integrity of pleura. If the pleura remains intact, mediastinitis sets in with rupture of mediastinal pleura, pneumothorax, or hydrothorax. If the pleura is not intact, EPF can occur with resultant decompression of oesophageal contents into the pleura and thus mediastinum may not be involved.
- 2. CLINICAL PRESENTATION:-** 55-year-old male chronic smoker came with complains of
  - Exertional breathlessness since 2 months
  - Cough with purulent expectoration since 2 months
  - Mild grade fever intermittent in nature since 2 months
  - Loss of appetite since 2 months.

Patient was not having any history of DM/HTN/IHD/PUL.TB/BA. No past surgical history. Patient was having complains since last 2 months. For this he used to consult some local doctor but did not get symptomatic relief.
- 3. EXAMINATION:-** Patient was a chronic smoker and alcoholic. Patient was conscious, oriented to time, place and person, afebrile. Thin built with BMI of 18.1 kg/m<sup>2</sup>. Clubbing present grade 2, pallor was present. No lymphadenopathy and icterus. His pulse was 90/min, blood pressure was 90/60 mmHg, oxygen saturation was 90% at room air, respiratory rate was 29 cycle/min., on auscultation bilateral rhonchi was present and breath sound was absent over right infrascapular and infra-axillary regions.
- 4. APPROACH TO DIAGNOSIS:** His investigation were as follows- HB -6.1 gm%, TLC -16780/cmm, PLATELETS- 411000/Cmm, SERUM UREA-14 mg/dl, CREATININE-0.6 mg/dl, TOTAL BILIRUBIN-0.3 mg/dl, DIRECT BILIRUBIN-0.1 mg/dl, SGOT-38 I.U./lit., SGPT-20 I.U./lit., ALKALINE PHOSPHATE-190 I.U./lit. Sputum examination- GRAM STAIN showed many polymorphonuclear cells and gram positive cocci. Negative for ACID FAST BACILLI on smear examination. CULTURE AND SENSITIVITY was sterile. HIV and HbsAg- Non-reactive. USG ABDOMEN- Mild ascites with minimal pleural effusion with collapse consolidation on right side. 2D ECHO: RA/RV dilated (COR PULMONALE), severe pulmonary hypertension (70mmHg), good LV systolic function. Chest X-ray (Fig- 1a & 1B)- suggestive of right mid and lower zone inhomogeneous opacity with cavitation.

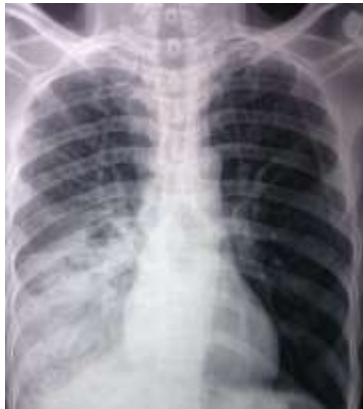

Fig-1a

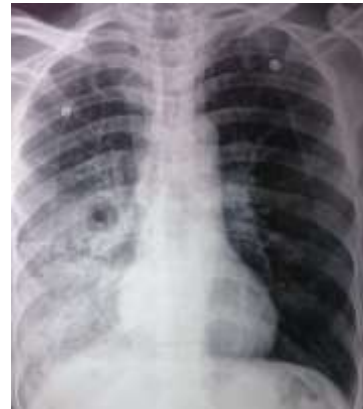

Fig-1b

CECT CHEST WITH HRCT (fig- 2a & 2b): Moderate loculated collection with multiple fluid levels in right pleural space with underlying collapse consolidation, RENT in lateral wall of oesophagus communicating with this collection. Possibility of oesophageal rupture.

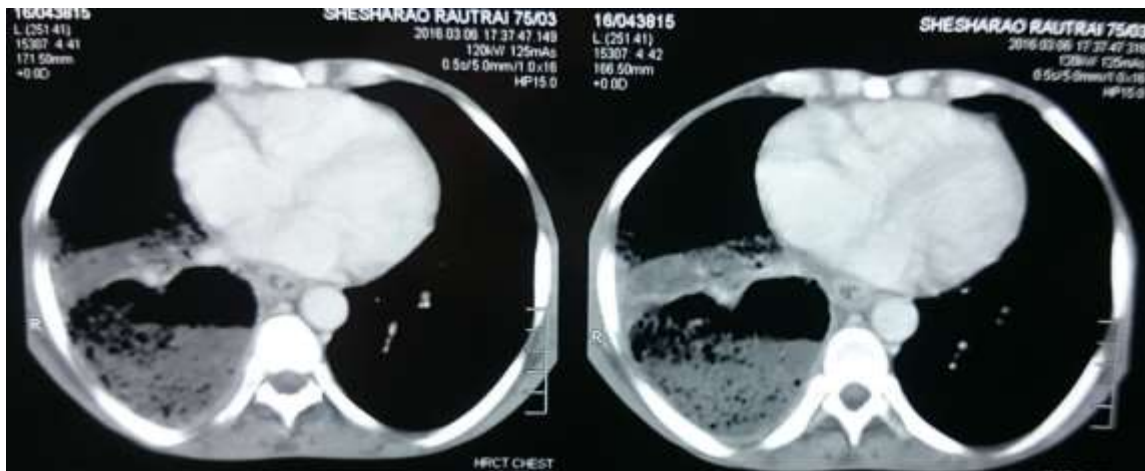


Fig-2a

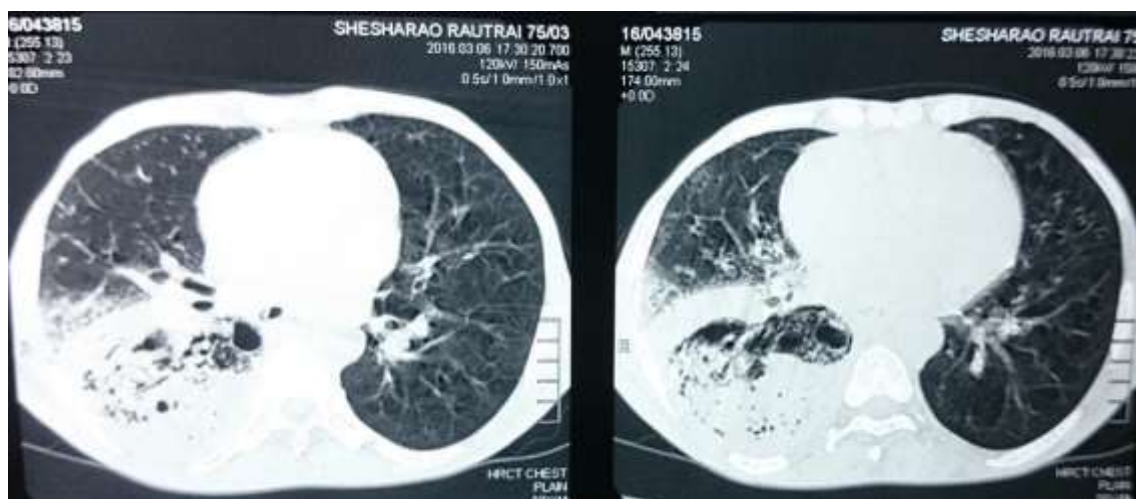

Fig-2b

OESOPHAGOGRAM done with oral contrast showing communicating fistula between oesophagus and pleura. (Fig- 3a, 3b)

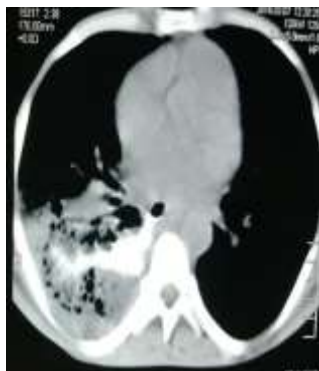

Fig- 3a

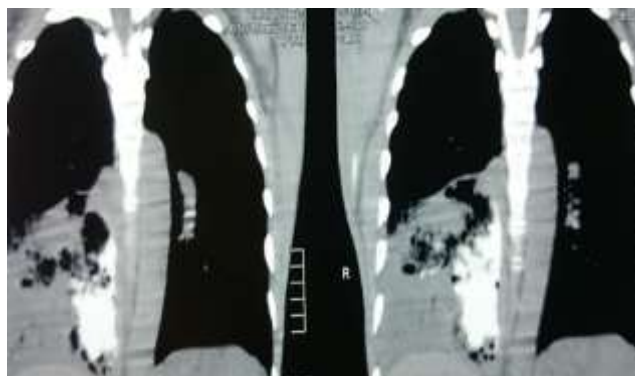

Fig-3b

GASTROSCOPY (fig- 4a, 4b, 4c): Neoplastic lesion in mid oesophagus with perforation of oesophageal wall leading to oesophagopleural fistula. Biopsy reports suggestive of squamous cell carcinoma.

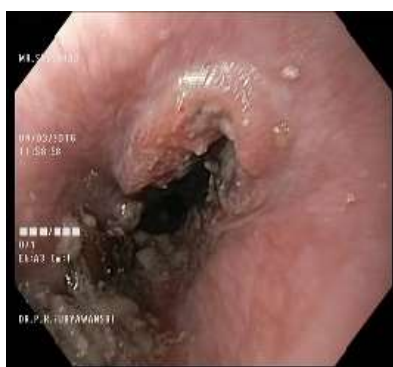

Fig-4a- Oesophageal growth

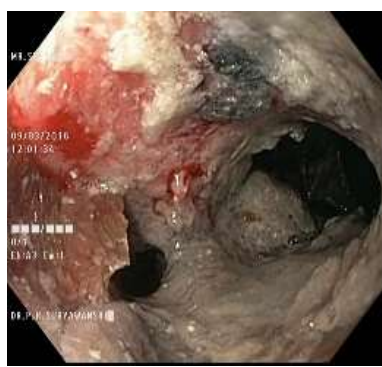

Fig-4b-oesophagus and oesophagopleural fistula

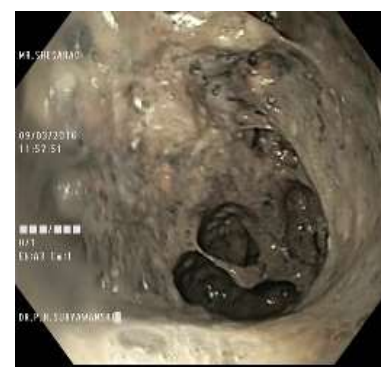

Fig-4c- Debris in pleura

5. **MANAGEMENT:-** Patient was started on antibiotic piperacillin tazobactam and metronidazole along with injectable and inhaled bronchodilators. After diagnosing oesophageal pleural fistula endoscopic guided nasogastric tube was inserted for feeding. Followed by right sided intercostal drain was secured giving patient symptomatic relief from breathlessness. Patient was then referred to oncologist and gastroenterologist for further management and treatment.

6. **DISCUSSION:-** Malignant esophagopleural fistula or esophagotracheal fistula occurs in approximately 5–15% of patients with esophageal cancer<sup>1,2</sup>. Fistulae further lead to development of complication in the mediastinum, trachea-bronchial tree, pleura, and lung which includes mediastinitis, empyema, and aspiration pneumonia<sup>3</sup>. Affected individuals may present with signs and symptoms of empyema, such as chest pain, high fever, and hypotension. Additional symptoms of dysphagia, odynophagia, or foul-tasting regurgitations should suggest the possibility of an esophagopleural fistula<sup>4</sup>. The presence of food particles or gastric contents in the pleural space confirms this diagnosis<sup>5</sup>. In patients with esophageal cancer, incidence of malignant esophageal-pleural fistula (EPF) is 5%-15%<sup>5,6</sup>. Such fistulas can develop during the early or late postoperative periods after pneumonectomy. Early fistulas may result from direct injury to the esophagus at surgery, particularly if tumor is dissected from the esophageal wall. Anatomically, the esophagus is in direct contact with the lung pleura for a considerable distance on the right side, whereas on the left side, the aorta lies in between the esophagus and the pleura, except for a short distance just above the diaphragm. Therefore, processes in the esophagus can spread more easily into the right side of pleura rather than the left.

7. **CONCLUSION:-** In our case, the cause of the esophagopleural fistula was unclear. Nonoperative management of esophagopleural fistulas is associated with mortality rates approaching 100%, whereas surgical repair is associated with mortality rates of approximately 50%. Self-expanding metal stents (SEMSs) have been considered a safe and effective treatment for malignant dysphagia, stricture, and fistula in inoperable patients.

**Reference: -**

1. Duranceau A, Jamieson GG. Malignant tracheoesophageal fistula. *Ann Thorac Surg* 1984;37(4):346–54.
2. Sarper A, Oz N, Cihangir C, Demircan A, Isin E. The efficacy of self-expanding metal stents for palliation of malignant esophageal strictures and fistulas. *Eur J Cardiothorac Surg* 2003;23(5):794–8.
3. Wechsler RJ (1986) CT of esophageal-pleural fistulae. *AJR Am J Roentgenol* 147: 907-909.
4. Massard G, Wihlm JM. Early complications. Esophagopleural fistula. *Chest Surg Clin N Am* 1999; 9:617-631 [Medline]
5. Duranceau A, Jamieson GG. Malignant trachea-esophageal fistula. *Ann Thorac Surg.* 1984; 37: 346-354. [http://dx.doi.org/10.1016/S0003-4975\(10\)60745-X](http://dx.doi.org/10.1016/S0003-4975(10)60745-X)
6. Sarper A, Oz N, Cihangir C, et al. The efficacy of self expanding metal stents for palliation of malignant esophageal strictures and fistulas. *Eur J CardiothoracSurg.* 2003; 23: 794-798. [http://dx.doi.org/10.1016/S1010-7940\(03\)00091-5](http://dx.doi.org/10.1016/S1010-7940(03)00091-5)